

## A retrospective morphometric analysis of adult female Chiari type I patients with commonly reported and related conditions

Maggie S. Eppelheimer, James R. Houston, Jayapalli Rajiv Bapuraj, Richard Labuda, Dorothy M. Loth, Audrey M. Braun, Natalie J. Allen, Soroush Heidari Pahlavian, Dipankar Biswas, Aintzane Urbizu, Bryn A. Martin, Cormac O. Maher, Philip A. Allen, Francis Loth

### Purpose

Researchers have sought to better understand CM1 through morphometric measurements beyond tonsillar position (TP). Soft tissue and bone structures within the brain and craniocervical junction have been shown to be different for CMI patients compared to healthy controls. CMI is also associated with different prevalent conditions (PCs) such as syringomyelia, pseudotumor, Ehlers-Danlos syndrome (EDS), scoliosis, and craniocervical instability. The goal of this study was two-fold: (1) to identify unique morphological characteristics of PCs, and (2) to better explain inconsistent results from case-control comparisons of CMI.

### Methods

Image, demographic, and PC information was obtained through the Chiari1000, a self-report web-accessed database. Twenty-eight morphometric measurements (MMs) were performed on the cranial MR images of 236 pre-surgery adult female CMI participants and 140 female healthy control participants. Custom software was used to measure 28 structures within the posterior cranial fossa (PCF) compartment, craniocervical junction, oral cavity, and intracranial area on midsagittal MR images for each participant

### Results

Morphometric analysis of adult females indicated a smaller McRae line length in CMI participants with syringomyelia compared to those without syringomyelia. TP was reduced in CMI participants with EDS than those without EDS. Basion to posterior axial line was significantly longer in CMI participants with scoliosis compared to those without scoliosis. No additional MMs were found to differ between CMI participants with and without a specific PC. Four morphometric differences were found to be consistently different between CMI participants and healthy controls regardless of PC: larger TP and a smaller clivus length, fastigium, and corpus callosum height in CMI participants.

### Conclusions

Syringomyelia, EDS, and scoliosis were the only PCs that showed significant morphometric differences between CMI participants. Additionally, four midsagittal MR-based MMs were found to be significantly different between healthy controls and CMI participants regardless of the presence of one or more PCs. This study suggests that the prevalence of comorbid conditions are not strongly related to CMI morphology, and that inconsistent findings in the radiographic literature cannot be explained by varying prevalence of comorbid conditions in CMI study samples.

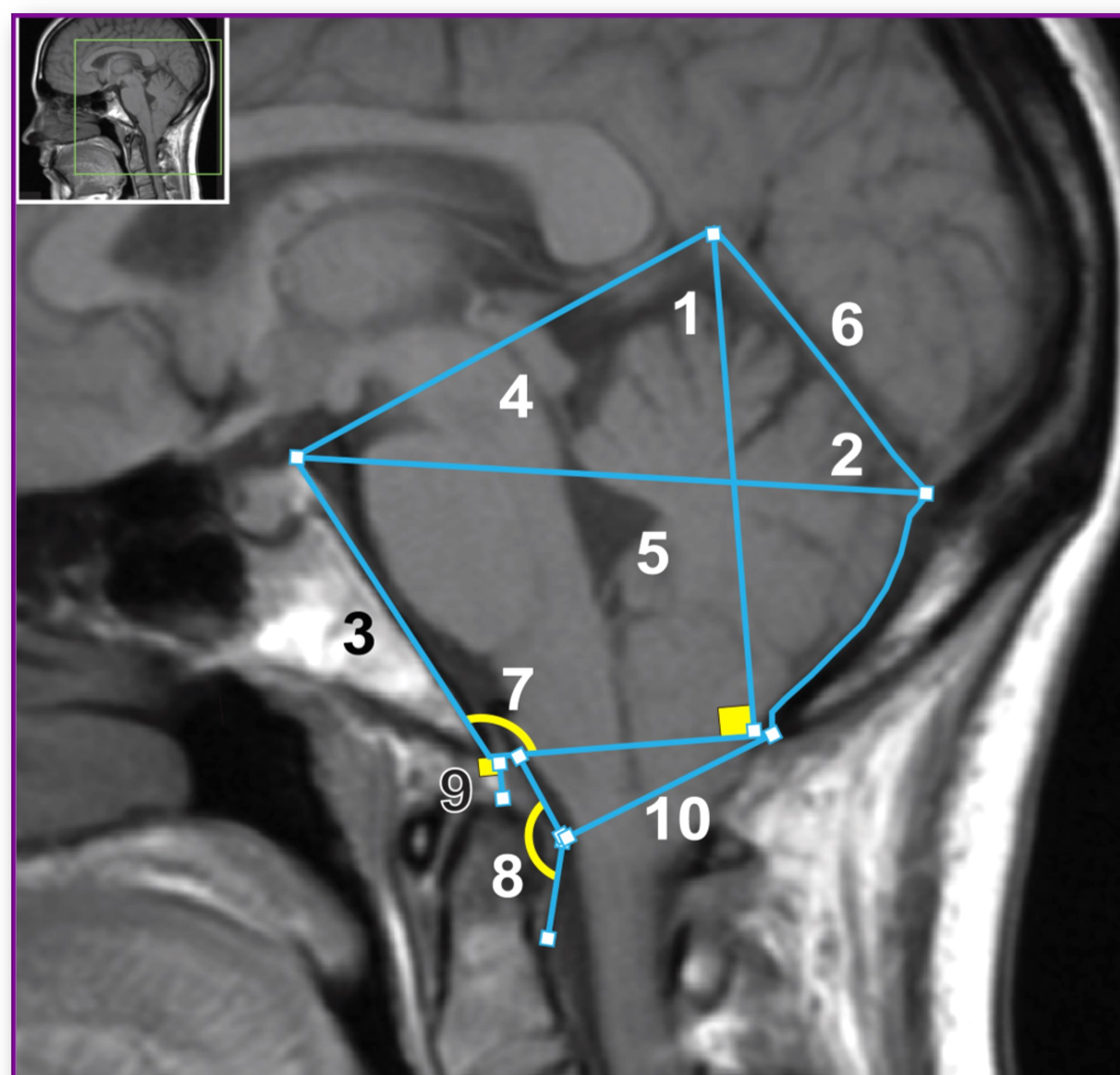


TABLE 2 | Prevalence of conditions in CMI sample with demographics.

Prevalent condition	N	Condition prevalence (%)	Mean age in years (stdev)	Percent caucasian (%)
Migraine headaches	147	62	36 (10)	91.2
<b>Scoliosis</b>	45	19	35 (10)	95.5
<b>Syringomyelia</b>	38	16	32 (10)	92.1
Fibromyalgia	33	14	37 (10)	93.9
Chronic fatigue syndrome	31	13	38 (11)	87.1
Spinal dysraphism	29	12	35 (10)	93.1
<b>Ehlers Danlos syndrome</b>	21	9	36 (10)	100.0
Other Endocrine Diseases	20	8	37 (11)	95.0
<b>Pseudotumor cerebri</b>	20	8	36 (12)	85.0
Raynaud phenomenon	18	8	38 (10)	94.4
<b>Craniocervical instability</b>	17	7	38 (10)	88.2
Sleep Apnea	16	7	41 (12)	93.8

Total CMI participants in study: 236. Conditions in bold are labeled as RC. Overall racial and ethnic prevalence in our sample: 2% Native American/Alaska Native, 2% Asian, and 6% Black/African American. PCs include some conditions that were diagnosed as a child.